

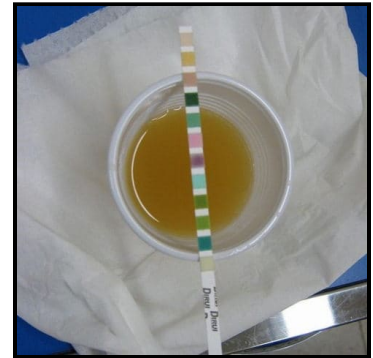


# Top 20 Canine Dx pt. 1

## 5 Of Zuku's Top 20 Canine Diagnoses To Know For NAVLE® Success:

### 1. Diabetes mellitus

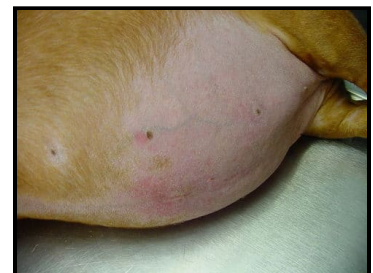- **Classic case:**
  - Polyuria and polydipsia
  - Increased appetite
  - Weight loss
  - Ketoacidosis: vomiting, inappetence, lethargy
- **Dx:**
  - Serum chemistries and urinalysis
  - Fructosamine gives estimation of blood glucose over the previous 2 weeks
- **Rx:**
  - Stable, non-ketotic diabetics
    - Long-acting insulin (NPH, Vetsulin)
    - Increase dietary fiber, Rx diabetic diet
  - Ketoacidotic or ill
    - Hospitalization with supportive care
    - Treat potassium or phosphorus derangements
    - Short-acting regular insulin until ketosis resolved
- **Pearls:**
  - Prognosis is good
  - Measure fructosamine to rule out stress hyperglycemia
  - Glucosuria can cause elevated urine specific gravity



*Urine dipstick screening for glucosuria in diabetes mellitus*

### 2. Hyperadrenocorticism (Cushing's disease)

- **Classic case:**
  - The 4 P's: polyuria, polydipsia, polyphagia, panting
  - Truncal alopecia
  - Potbellied appearance
  - Thin skin/cutaneous atrophy
  - Calcinosis cutis
  - 3 types:
    - Pituitary dependent hyperadrenocorticism (PDH)
    - Adrenal dependent hyperadrenocorticism (ADH)
    - Iatrogenic
- **Dx:** None are very sensitive in early disease
  - Chemistry profile: ALP elevation, hypercholesterolemia
  - CBC: stress leukogram (neutrophilia, lymphopenia, eosinopenia), thrombocytosis
  - Urinalysis: hyposthenuria, +/- proteinuria
  - Urine cortisol:creatinine
    - If normal, rules out hyperadrenocorticism
    - If abnormal, further testing needed
  - ACTH stimulation test: test of choice for iatrogenic hyperadrenocorticism
  - Low-dose dexamethasone suppression test (LLDS): higher sensitivity for hyperadrenocorticism
  - Endogenous ACTH
    - Differentiates PDH from ADH

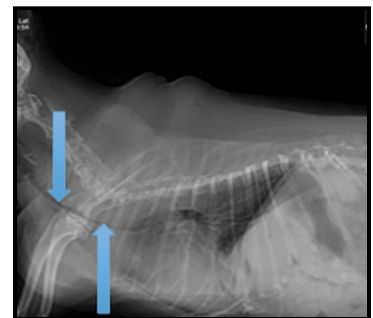


*Cushingoid Dachshund with potbelly and cutaneous atrophy*

- Limited usefulness because of high rate of false low values
- High-dose dexamethasone suppression test
  - PDH: 75% will suppress, 25% will not
  - ADH: will not suppress
- Abdominal ultrasonography
  - PDH: bilateral normal-to-plump adrenals
  - ADH: single enlarged adrenal gland, contralateral is small or non-visible
- **Rx:**
  - PDH
    - Trilostane: inhibits enzyme key to cortisol production
    - Lysodren: causes necrosis and destruction of cortisol-secreting portions of adrenals
    - Surgical: hypophysectomy or bilateral adrenalectomy
      - Requires referral, limited availability
      - Lifelong hormonal therapy post-op
    - Radiation, especially stereotactic radiotherapy or radiosurgery
  - ADH
    - Surgical: adrenalectomy, requires referral
    - Medical
      - Trilostane or lysodren
      - Lysodren may result in neoplastic adrenal gland necrosis
  - Iatrogenic
    - Change to oral, short-acting steroid
    - Gradually decrease dosage over several weeks
    - Do ACTH stimulation test to see if steroids can be discontinued
- **Pearls:**
  - Guarded to good prognosis
  - Stereotactic radiosurgery and radiotherapy are promising treatments for pituitary tumors

### 3. Collapsing trachea

- **Classic case:**
  - Toy and small breeds
  - Middle aged
  - “Honking” cough exacerbated by excitement or activity
  - Retch at end of cough
  - Severe cases: cyanosis or exercise intolerance
- **Dx:**
  - Thoracic radiographs: may be hard to catch dynamic collapse
  - Fluoroscopy
  - Endoscopy: requires anesthesia
- **Rx:**
  - Medical
    - Short course of corticosteroids
    - Cough suppressant
    - Weight loss if overweight
  - Tracheal stent
    - If refractory to medical management
    - Requires referral
- **Pearls:** Always radiograph to rule out pulmonary edema as cause of cough



*Radiograph of collapsing cervical and cranial thoracic trachea*

### 4. Immune-mediated hemolytic anemia (IMHA)

- **Classic case:**
  - Lethargy, weakness, pallor
  - Tachypnea
  - Icterus
  - Variable organomegaly

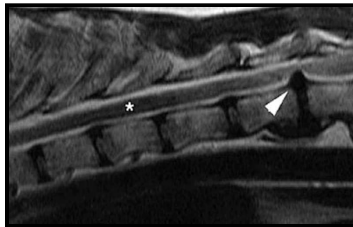
- Discolored urine from hemoglobinuria or bilirubinuria
- **Dx:**
  - CBC: anemia, +/- elevated reticulocytes, spherocytes, polychromasia, anisocytosis
  - Saline slide agglutination test
  - Coombs test: for antibodies against RBCs
  - Imaging to look for neoplasia
  - Infectious disease testing
- **Rx:**
  - Immunosuppression: prednisone, azathioprine, cyclosporine, mycophenolate
  - Blood transfusion
  - Prevent thromboembolism: aspirin, low molecular weight or unfractionated heparin
- **Pearls:**
  - Prognosis is guarded
  - Regenerative anemia expected with IMHA, but bone marrow needs 3-5 days to respond



*Hematocrit tubes showing icteric serum and low PCV in immune-mediated hemolytic anemia*

## 5. Intervertebral disk disease (IVDD)

- **Classic case:**
  - PAIN in neck or back – arched back or head held down
  - Ataxia, paraparesis, or paraplegia
  - Tetraparesis
- **Dx:**
  - MRI: safe, fast, and best quality
  - CT: safe and faster than MRI but lower quality
  - Myelography: invasive and seizures may occur during recovery
- **Rx:**
  - If pain only (no neuro signs): strict cage rest and analgesia with opiates or NSAIDs
  - Nonambulatory or unresponsive to conservative treatment: surgical decompression by experienced neurologist or surgeon
    - Hemilaminectomy for thoracolumbar disks
    - Ventral slot for cervical disks
  - Steroids are **increasingly unpopular for pain control**
    - Falling out of favor with surgeons and neurologists because of numerous adverse effects and poor efficacy
    - Better results with NSAIDs
- **Pearls:**
  - Hansen type I occur in chondrodystrophoid breeds and the nucleus pulposus extrudes through the annulus
  - Hansen type II are usually nonchondrodystrophoid breeds with hypertrophy or bulging of the annulus
  - Prognosis:
    - If ambulatory: excellent
    - If nonambulatory with deep pain awareness: guarded (without surgery) to excellent (with surgery)
    - If nonambulatory with no deep pain awareness: 50% chance of regaining function if surgery occurs within 24 hours



*MRI showing herniated disk (arrowhead)*

Images courtesy of [Groom Da Oger](#) (urinalysis), [Caroldermoid](#) (potbelly), Laura Cousins, DVM, MS, DACVIM (tracheal collapse, hematocrit tubes), [NeuroWebVet](#) (MRI of ruptured disc), [BorhanLee](#) (cute dachshund) and [Carterse](#) (dog catching bubble).

© 2020 ZukuReview.com - All Rights Reserved